

Requisition form for Prenatal Screening

Patient Details:

Name: AKITHA SHREE SK
 Address: 17 & 18, 16th Cross, Akshaynagar 2nd block, ICPLaya Main road, Ramurthy Nagar, B'lore
 City: BANGALORE State: KARNATAKA
 Contact Number: 8792566194
 Email address: sikitha.shree.sk.588@gmail.com
 DOB: 15/02/2000 Weight: 74 kg Height: 139 cm
 Ethnicity: Asian Caucasian African Other Folic acid intake: Yes No
 Smoking: Yes No

Requesters Information:

Name of Hospital/Collection Centre: RMA
 City:
 Name of Ordering Physician: Dr. W.M.N.
 Contact number of Ordering Physician:
 Name of Sonographer: Dr. Ashwin
 FMF code (if available):

Pregnancy History:

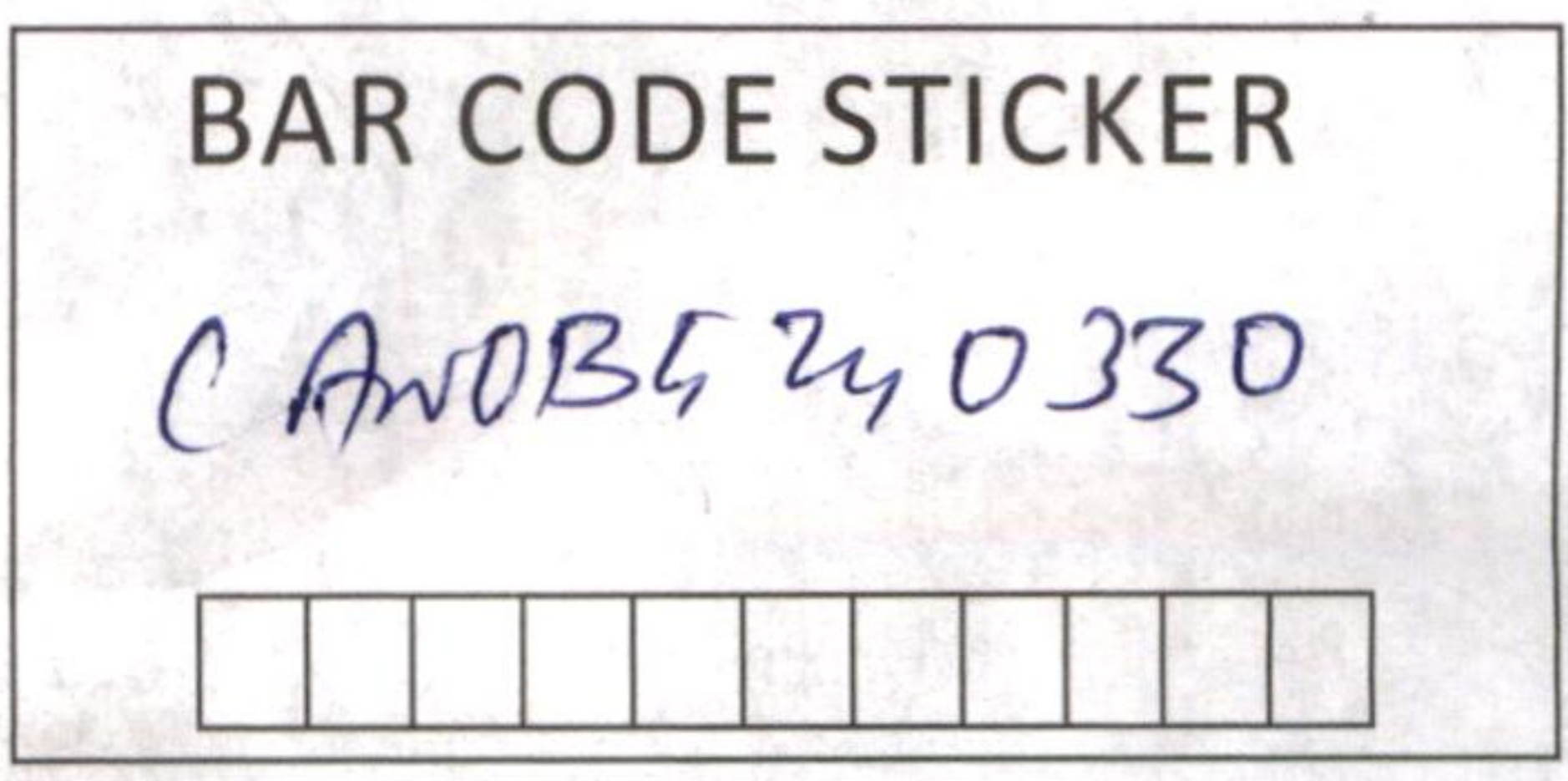
LMP: 01/03/2024 USG/Corr EDD: DDMMYY
 LMP certainty: Regular Irregular Unknown
 Parity: Gravida Para Abortion Live
 Present pregnancy: Singleton Twin
 Previous pregnancy: History of Down syndrome Yes/No Yes No
 Previous pregnancy: History of Edwards' syndrome / Patau syndrome / ONTD Yes/No Yes No
 Diabetes status: Insulin dependent Please Specify MMYY Gestational
 Patient on HCG: Yes No If yes, latest date of HCG intake DDMMYY
 Bleeding/Spotting in last two weeks: Yes No
 Type of Conception: Natural Assisted Ovulation drugs
 If assisted reproduction, kindly mention the type of procedure:
 Extraction date: DDMMYY Transfer date: DDMMYY

Egg source: Self/ donor. If donor, then donor's age/DOB DDMMYY
 Patient Consent: I have read understood test requisition form for prenatal screening and pre-eclampsia. I consent that my sample shall be the sole exclusive property of Cancyte and I transfer all my sample rights to Cancyte for its research and / or commercial use



Memorial Hospital
60 004, INDIA.

17 JUN 2024



Sample Collection time: DDMMYY am/pm
 Sample Collected By:

Ultrasound History

First trimester ultrasound details
 USG date: 06/06/2024
 CRL: 72.4 mm NT: 2.5 mm
 NB: Present Absent

Twin pregnancy ultrasound details
 USG date: DDMMYY
 DCDA: MCDA: MCMA:

CRL	Twin A	Twin B
NT		
NB		

Second trimester ultrasound details
 USG date: DDMMYY
 BPD: mm
 FL: mm
 HC: mm

Second trimester Screening (STS) (15wks to 21.6 wks)

STS cannot be performed in twin pregnancy

Early Biochemistry: (10-11 wks) with NT at 11-13.6 wks (Free β HCG / PAPP-A)
 Biochemistry combined with NT+ Free β HCG/PAPP-A
 Biochemistry only (Free β HCG/PAPP-A):
 First trimester Enhanced: (AFP + Free β HCG + PAPP-A + PLGF)
 Pre-eclampsia* (PLGF + PAPP-A+MAP+UAD)

Triple marker test: AFP+Free β HCG + Unconjugated Estriol
 Quadruple test: AFP + Free β HCG + Unconjugated Estriol + Inhibin A
 Integrated Screening: AFP only
 SFLT / PLGF

Thalassemia Screening

-Thalassemia (HPLC) Iron Therapy - Yes/No (Kindly send CBC/CBC/DOC, Blood transfusion History)

Pre-eclampsia: Blood pressure (BP) history

Markers	Left arm	Right arm	MAP
Blood pressure (mm/Hg)	Systolic BP	Systolic BP	Diastolic BP
First reading	<u>100</u>	<u>70</u>	<u>90</u>
Second reading	<u>100</u>	<u>70</u>	<u>70</u>

Family History of Pre-eclampsia: Not known No Patient
 Chronic Hypertension: Not known No Medication Untreated
 Uterine Artery pulsative index (UAD-PI): Right PI: 3.6 Left PI: 3.2 (ua doppler acceptable range: 0.4 - 4)

BP (sugar) = Father

Important: 1) This form has to be completely filled up for us to process the sample. 2) Sample(s) accepted are subject to verification at our Laboratory. If sample found unfit for processing, the healthcare professional will be notified. 3) Kindly attach relevant copy(s) of diagnostic report(s)

Signature of the Patient: Y Likhita SK
 Signature of Ordering Physician:

Patient name	Mrs. LIKITHA SHREE S K	Age/Sex	23 Years / Female
Patient ID	2075345	Visit no	3
Referred by	WMN DOCTORS	Visit date	06/06/2024
LMP date	01/03/2024, LMP EDD: 06/12/2024[13W 6D]		

OB - First Trimester Scan Report

Indication(s)

NT SCAN

G1

Real time B-mode ultrasonography of gravid uterus done.

Route: Transabdominal

Single intrauterine gestation

Very poor penetration of sound waves.

Right Uterine	3.6	┆┆┆┆●
Left Uterine	3.2	┆┆┆┆●
Mean PI	3.4	┆┆┆┆●

Fetus

Survey

Placenta - Posterior

Liquor - Normal

Fetal activity present

Cardiac activity present

Fetal heart rate - 159 bpm

Biometry(Hadlock,Mediscan)

BPD 22.6 mm 13W 5D (2%ile)	HC 85.5 mm 13W 5D (11%ile)	AC 71.6 mm 13W 5D (18%ile)	FL 10.9 mm 13W 2D (9%ile)
<< 	* 	* 	*

CRL - 72.4 mm(13W 2D)

Patient name	Mrs. LIKITHA SHREE S K	Age/Sex	23 Years / Female
Patient ID	2075345	Visit no	3
Referred by	WMN DOCTORS	Visit date	06/06/2024
LMP date	01/03/2024, LMP EDD: 06/12/2024[13W 6D]		

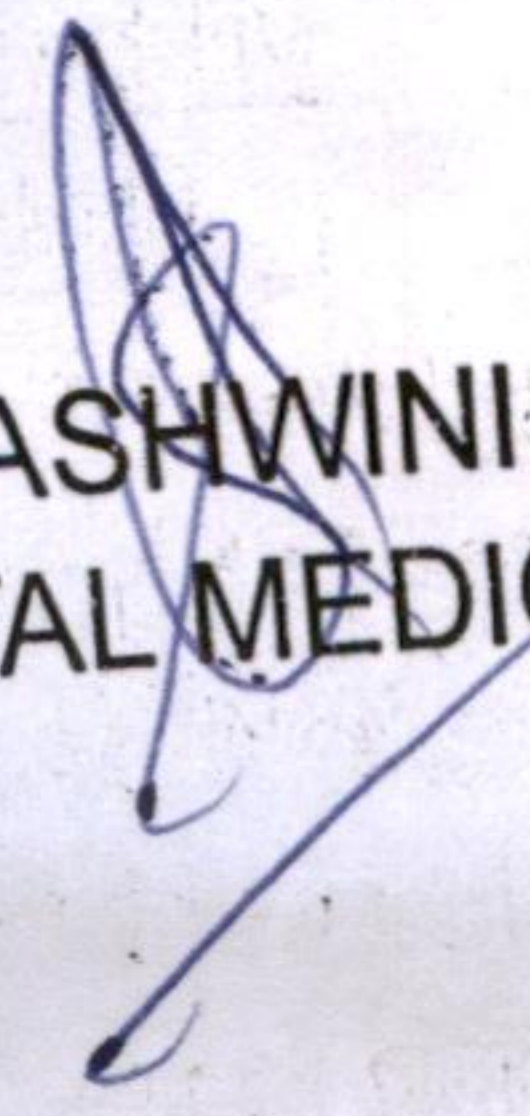
I DR ASHWINI JA, declare that while conducting ultrasonography on Mrs. LIKITHA SHREE, I have neither detected nor disclosed the sex of her foetus to anybody in any manner.

Please Note: All congenital anomalies cannot be detected on antenatal scan

First trimester screening for Downs

Maternal age risk 1 in 1394

Fetus	Risk estimate - NT	Risk estimate - NT + NB
A	1 in 1742	1 in 5808


 DR ASHWINI JA
 FETAL MEDICINE CONSULTANT KMC NO 88007