

Sample Collection date: 13/12/2023 am/pm
 Sample Collection time: 03:00
 Sample Collected By: H-STAFF

Patient Details:
 Name: Mrs. SARITA SHARMA
 Address: KANPUR
 City: KANPUR State: U.P.
 Pin: 9169701026
 Email ID: 01011991
 DOB: 01/01/1991 Weight: 73.kg Height: 4.9.m
 Ethnicity: South Asian East Asian African Other Smoking status: Yes No

Requesters Information:
 Name of Hospital/Collection Centre: SHYAM CHILDREN SCENTER
 City: KANPUR
 Name of Ordering Physician: Dr. NEERA DIXIT
 Name of Sonographer: Dr. ALOR KUMAR
 FMF code (if available):

Pregnancy Details:
 LMP: 03/09/2023 USG/Corr EDD: D D M Y Y Y
 LMP certainty: Regular Irregular Unknown

Obstetric History:
 Parity (pregnancy at ≥24 weeks): Gravida: 2 Abortion: Live: 1
 Details of last pregnancy at ≥ 24 weeks
 PE: Yes No Date of delivery: D D M Y Y Y
 GA at delivery: ___ Weeks ___ Days

Present pregnancy: Singleton Twin Vanishing Twin
 Type of Conception: Natural Assisted Ovulation drugs
 If assisted reproduction, kindly mention the type of procedure
 Extraction date: D D M Y Y Y Transfer date: D D M Y Y Y
 Egg source: Self donor. If donor, then donor's age/DOB: Type 1 Type 2
 Diabetes: Yes No If Yes, Type: Gestational Type 1 Type 2
 Treatment method: No treatment / Insulin / Metformin / Insulin+Metformin / Diet Control
 If on Insulin, Insulin start date: D D M Y Y Y
 Patient on hCG: Yes No If yes, latest date of hCG intake: D D M Y Y Y
 Bleeding/Spotting in last two weeks: Yes No

Previous pregnancy History:
 History of Down Syndrome: Yes No Edwards' Syndrome: Yes No Patau Syndrome: Yes No ONTD: Yes No
 History of Systemic Lupus Erythematosus: Yes No History of Anti Phospholipid Syndrome (APLA): Yes No

I agree to be contacted by Lilac Insights for information regarding their tests and updates.

Requisition form for Prenatal Screening

Ultrasound History
First trimester ultrasound details
 USG date: 13/12/2023
 DCDA MCDA MCMA
 CRL: 40 mm NT: 1-2.6 mm
 NB: Present Absent

Twin pregnancy ultrasound details
 USG date: D D M Y Y Y
 Twin A: Present Absent
 Twin B: Present Absent

Second trimester ultrasound details
 USG date: D D M Y Y Y
 BPD: _____ mm
 FL: _____ mm
 HC: _____ mm

TEST REQUESTED

First trimester Screening (FTS) (10 weeks to 13.6 weeks)
 1. Combined First Trimester Screening
 2. First Trimester Screening + Pre-eclampsia (without PIGF)
 3. First Trimester Screening + Pre-eclampsia (with PIGF)
 4. Early Biochemistry
 5. Only Biochemistry values
 6. Biochemistry Only
 7. First Trimester Enhanced
 8. First Trimester Enhanced + Pre-eclampsia (with PIGF)

Second trimester Screening (STS) (15 weeks to 21.6 weeks)
 STS cannot be performed in twin pregnancy
 9. Triple marker test
 10. Quadruple marker test
 11. Quadruple- Integrated Screening

Pre-eclampsia Screening
 (PIGF + PAPP-A + MAP + UAD)
Pre-eclampsia and Fetal Growth Restriction:
 Blood pressure (BP) history BP measurement date: D D M Y Y Y

Markers	Left arm	Right arm
Blood pressure (mm/Hg)	Systolic BP	Systolic BP
	Diastolic BP	Diastolic BP
First reading		
Second reading		
The difference should not be more than 10 mm/Hg in first and second reading		
Family History of Pre-eclampsia: Not Known	<input type="checkbox"/>	<input type="checkbox"/>
Chronic Hypertension: Not known	<input type="checkbox"/>	<input type="checkbox"/>
Uterine Artery pulsative index (UAD-PI):	Right PI	Left PI
Previous small baby:	<input type="checkbox"/> Yes <input type="checkbox"/> No	<input type="checkbox"/> Yes <input type="checkbox"/> No

Thalassemia Screening Thalassaemia (HPLC) Iron Therapy - Yes/No (Kindly send CBC/DOC, Blood transfusion History)

Important: 1) This form has to be completely filled up for us to process the sample. 2) Sample(s) accepted are subject to verification at our Laboratory. If sample found unfit for processing, the healthcare professional will be notified. 3) Kindly attach relevant copy(s) of diagnostic report(s).

Signature of the Patient: Sarita Signature of Ordering Physician: _____



For PAPP β-hCG: AFP: PIGF: uE3: Inhibin A: sFlt-1:



ALOK DIAGNOSTICS

IMAGING, PATHOLOGY & BIOPSY CENTRE

96 Slice CT Scan • 4D Ultrasound • Colour Doppler • Echo • Digital X-Ray • Pathology • Biopsy

113/24-B, Inderjeet Jain Marg, Lane Next to Police Station, Swaroop Nagar, Kanpur • Mob.: 7052151801
Dr. Alok Kumar Sinha
MD Radiodiagnosis, PDCC (SGPGI)

Dr. Supriya Katiyar
MD Pathology, (K.G.M.U.), Lucknow

Patient Name	: Mrs. Sarita Sharma	Date: 13-Dec-23
Referred By Name	: Dr. Neera Dixit	Age/Sex:- 34 Yrs./F
Investigation	: Ultrasound Fetal Well being	

OBSERVATION

Time since L.M.P - 14 Weeks 3 Days.

- ❖ Post LSCS configuration, Bulky gravid uterus with normal thickness gestational sac with single live foetus of ~ 7.66 cm C.R. length corresponding to 13 weeks 5 days gestational age.
- ❖ F.H.R - 159 Beats Per Minute.
- ❖ Placenta is fundus-anterior with grade 0 maturity, reaching upto internal os.
- ❖ Bilateral adnexa clear.
- ❖ No free fluid in cul-de-sac.
- ❖ Internal os closed.
- ❖ Cervical length - 4.0 cm (adequate).
- ❖ Nuchal translucency is within normal limit (1.26 mm).

Material - Evidence of heterogeneous hypoechoic area noted in posterior myometrium measuring ~ 2.7 x 2.4 cm -? Significance / ? Associated small degenerating fibroid.

IMPRESSION -

- ✓ Single live intrauterine fetus at 13 weeks 5 days of gestation.

Please correlate clinically

Declaration of Doctor conducting ultrasonography

I, Dr. Alok Kumar declare that while conducting ultrasonography / image I have neither detected nor disclosed the sex of her fetus to any body in any manner.


Dr. Alok Kumar

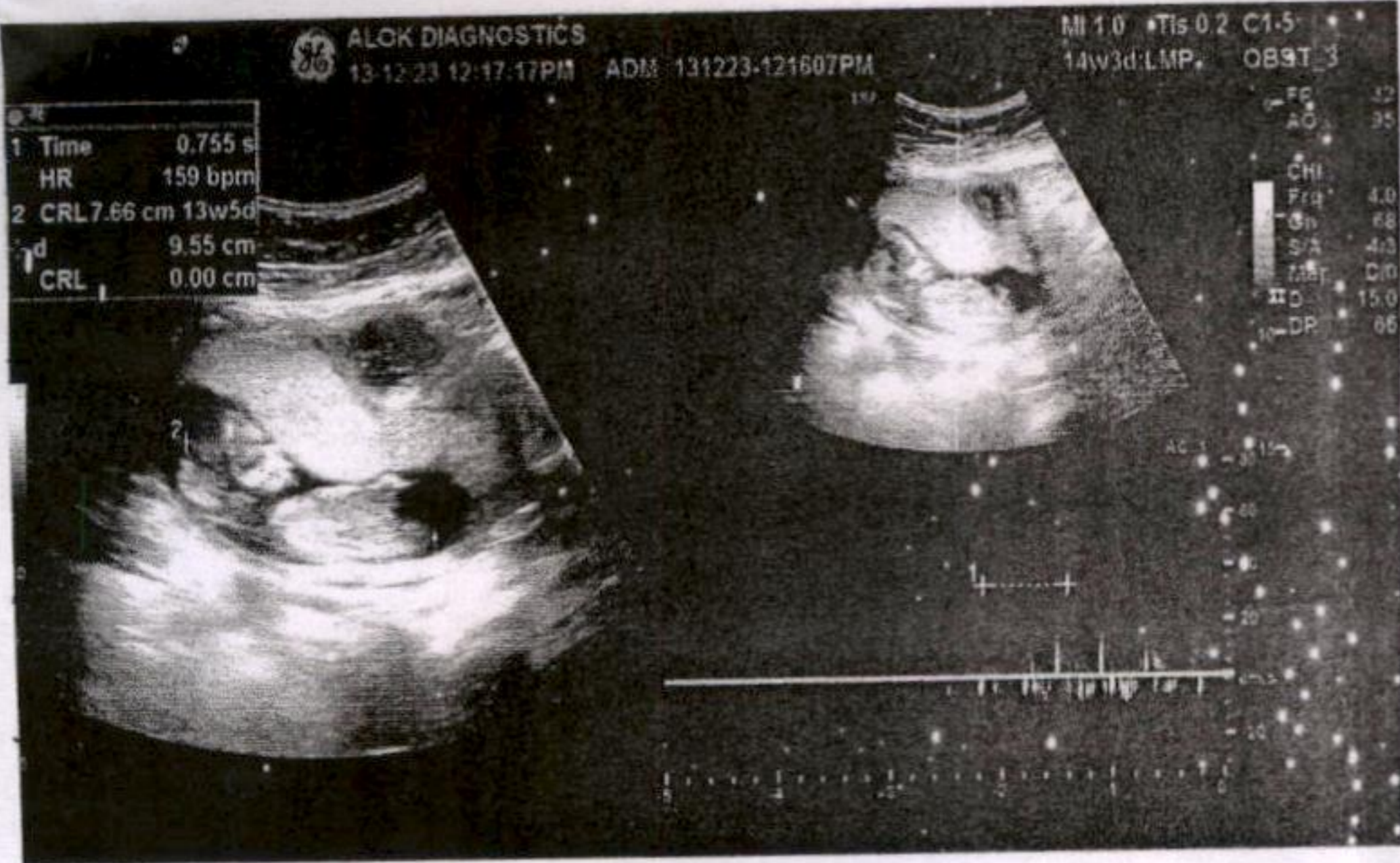
MD Radiodiagnosis
PDCC (Neuroradiology), FRCR (1), London
Ex-Senior Resident SGPGI, Lucknow
Formerly in PGI, Chandigarh & CMC, Vellore
(Consultant Radiologist)

Kindly Note

- ❖ Please Intimate us for any typing mistakes and send the report for correction within 7 days.
- ❖ The science of Radiological diagnosis is based on the interpretation of various shadows produced by both the normal and abnormal tissues and are not always conclusive. Further biochemical and radiological investigation & clinical correlation is required to enable the clinician to reach the final diagnosis.

The report and films are not valid for medico-legal purpose.



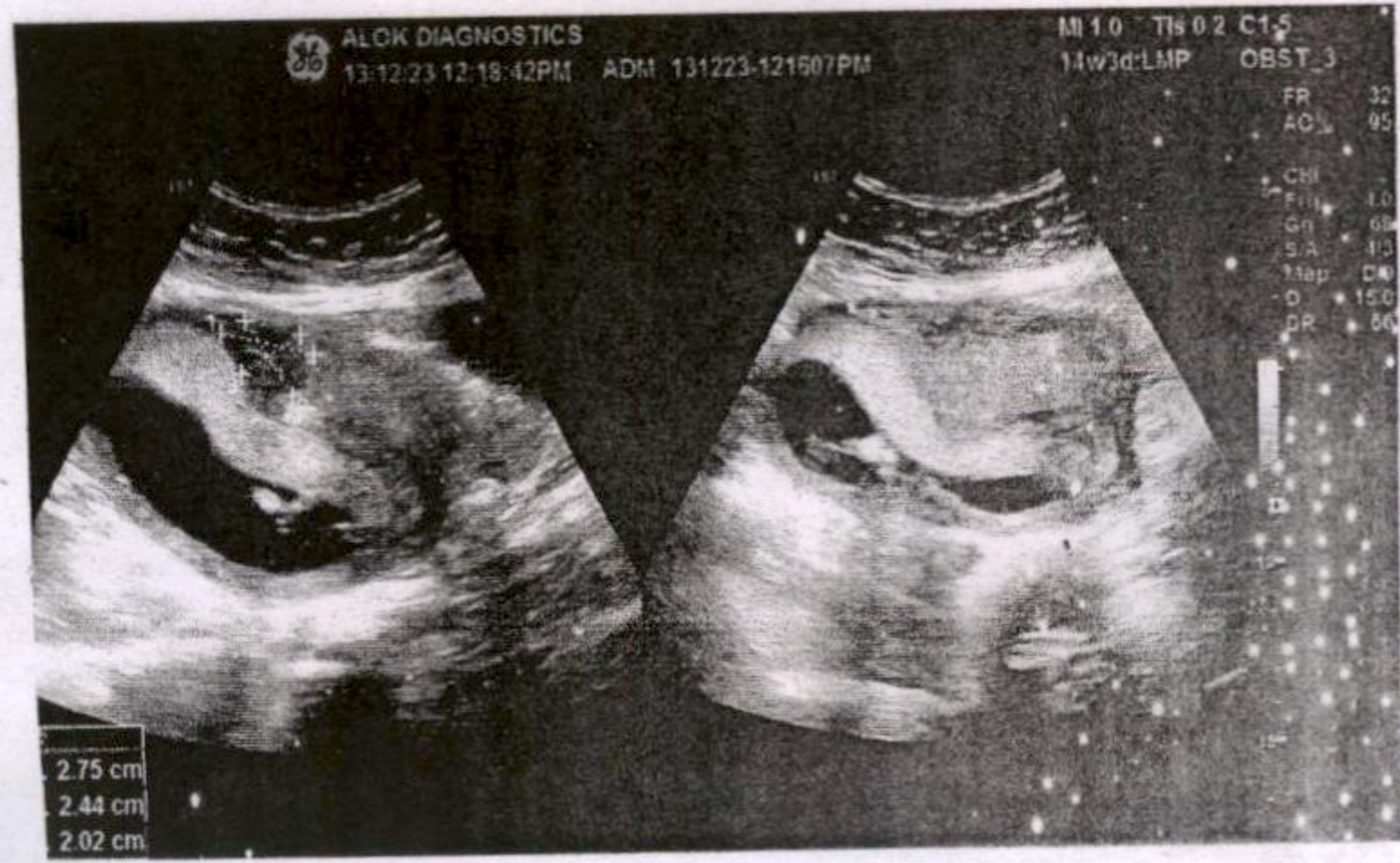


ALOK DIAGNOSTICS
13/12/23 12:16:58PM ADM 131223-121607PM * 14w3d:LMP

Origin	LMP	LMR	03/09/2023	BBT	GA	14w3d	EDD(LMP)	09/06/2024
Fetus A/I				AUA	13w5d+/- 1w2d		EDD(AUA)	14/06/2024
Fetus Pds				PLAC		Ref.Physician		Page 1/1

B Mode Measurements					
CRL(Hadlock)	<input checked="" type="checkbox"/>	7.66 cm	7.66	Last	13w5d 13w1d-14w3d

Doppler Measurements					
OB 2/3					
Time		0.755 s	0.755		Max.
HR		159 bpm	159		



DOB - 07/01/1991 Dwell Need
WT - 73 kg Wise
BMD - 2nd
MOR - 9169701026
_____→