

To: Dr. Balabhai Nanavati Hospital  
S.V. Road,  
Vile Parle (West)  
Mumbai- 400056  
Maharashtra  
Report Of: B/O ANJALI SUBHASH SONKUSARE



Sample ID : 2300131986  
Patient ID : 1002353485  
Collected on : 11-07-2023  
Received on : 12-07-2023 05:55:00  
Reported on : 23-07-2023 13:57:11  
Ref By : Dr. Balabhai Nanavati  
Hospital

### CONVENTIONAL KARYOTYPING REPORT

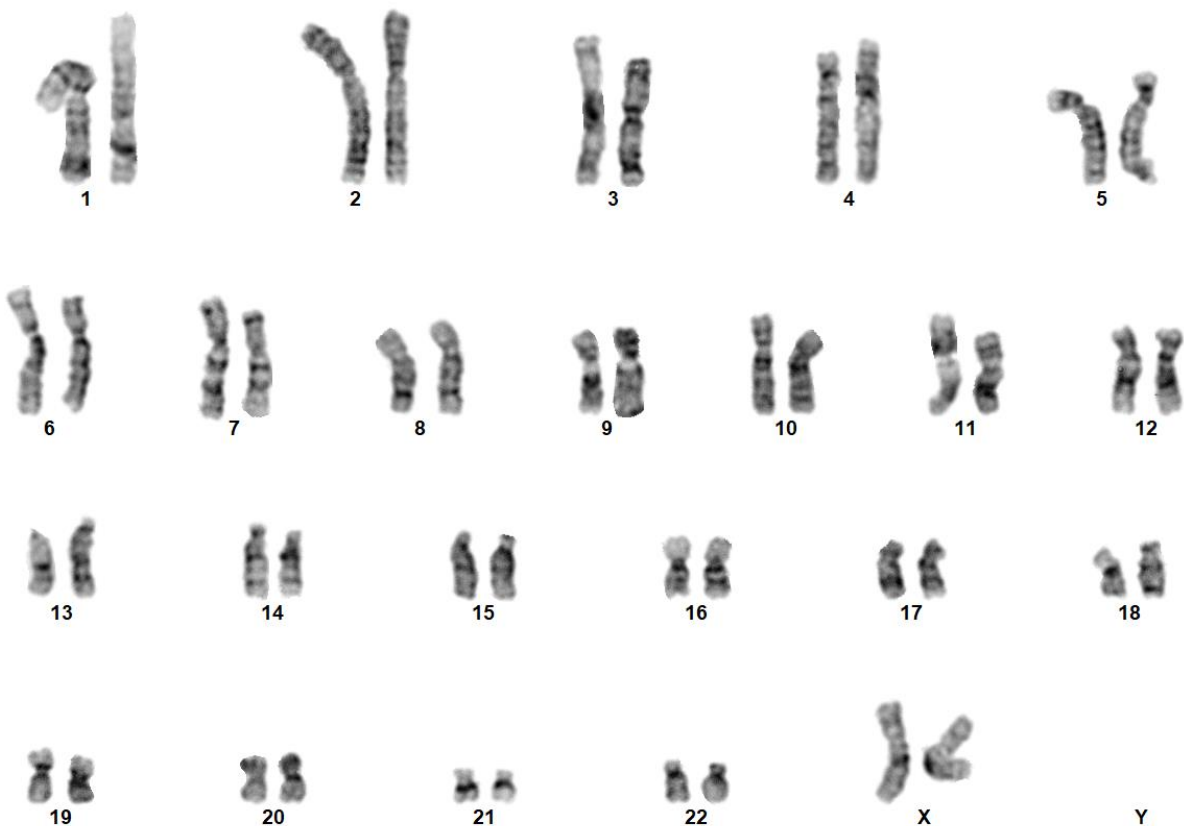
<b>Patient Name</b>	: B/O ANJALI SUBHASH SONKUSARE	<b>Age</b>	: 1 Month
<b>Physician Name</b>	: DR.NANAVATI HOSPITAL	<b>Gender</b>	: Female
<b>Provisional Diagnosis</b>	: Acute leukemia(AL)	<b>Specimen Status</b>	: Ok
<b>Specimen Type</b>	: Bone Marrow Aspirate (BMA)	<b>Disease Status</b>	: At Diagnosis
<b>Test Requested</b>	: Conventional Karyotype		

<b>Test</b>	: Conventional Karyotype Analysis.
<b>Method</b>	: 24-48 hr unstimulated culture of bone marrow aspirate followed by metaphase cells preparation, GTG Banding, karyotype analysis.
<b>No. of Metaphase Cells Analyzed</b>	: 20
<b>No. of Metaphase Cells karyotyped</b>	: 20
<b>Result</b>	: 46,XX[20]
<b>ISCN</b>	: 2020
<b>Band Resolution</b>	: 400

**Interpretation:** Conventional Karyotype analysis revealed normal diploid female karyotype 46,XX in all 20 cells.

**References:**

1. P. S. Kadam Amare, H. Jain, S. Kabre, Y. Deshpande, P. Pawar, S. Banavali, H. Menon, M. Sengar, B. Arora, N. Khattry, G. Narula, D. Sarang, S. Kaskar, B. Bagal, H. Jain, Uma Dangi, P. G. Subramanian, S. Gujral. Cytogenetic Profile in 7209 Indian patients with de novo Acute Leukemia: A Single Centre Study from India. *Journal of Cancer Therapy* 7: 530-544, 2016. DOI:10.4236/jct.2016.77056.
2. Mitelman F, Johansson B, Mertens F (eds). *Mitelman Database of Chromosome Aberrations and Gene Fusions in Cancer*, 2013, <http://cgap.nci.nih.gov/Chromosomes/Mitelman>.
3. Daniel A. Arber, Attilio Orazi, Robert Hasserjian, Jurgen Thiele, et al. The 2016 revision to the World Health Organization classification of myeloid neoplasms and acute leukemia. *Blood* 127:2391-2405, 2016; doi: <https://doi.org/10.1182/blood-2016-03-643544>.
4. Steven H. Swerdlow, Elias Campo, et al. THE UPDATED WHO CLASSIFICATION OF HEMATOLOGICAL MALIGNANCIES. The 2016 revision of the World Health Organization classification of lymphoid neoplasms. *Blood*. 2016;127(20):2375-2390.



46,XX

Prepared By : **Snehal Kaskar**  
Verified By : **Dr. Hrushikesh Lele**



**Dr. P. S. Kadam Amare**  
**Oncogeneticist**  
**Chief & Lab Director "Cancer &**  
**Clinical Genetics"**  
**Lilac Insights Pvt. Ltd.**



**Dr. Hrushikesh Lele**  
**Sr. Scientific Officer**  
**Oncocytogenetics Dept.**  
**Lilac Insights Pvt. Ltd.**

- End of Report -

Conditions of Reporting/Disclaimer:

- The report relates only to the specimen submitted to the lab which was verified and confirmed at the time of specimen collection. Also it is presumed that the specimen belongs to the patient named or identified, such verification being carried out at the point of generation of the said specimen.
- Although Conventional karyotyping is a gold standard method of cytogenetics which gives a global whole genomic view of multiple known, unknown chromosomal abnormalities, small cryptic, subtle aberrations below 7-8 Mb resolution can be missed.
- In spite of known sensitivity and efficiency of the genetic test, the test results have to be correlated with other clinical and pathological finding for conclusive diagnosis and disease management.
- A test request may be revised or generated by Lilac geneticist with an intimation to an Oncologist if: 1) Incomplete requisition 2) After haematopathology Update.
- In 1-2 % of APL cases, FISH may turn out to be negative due to PML/RARA probe design which unable to detect cryptic insertion of PML to RARA. In such rare cases, It is advisable to check PML-RARA by molecular methods.
- In case of Multiple Myeloma, flowcytometry report indicating abnormal plasma cell population is important for reference, as small abnormal clones may get deduced as per limit of detection policy in FISH analysis.
- In case of FFPE FISH, if H & E stained slides &/or histopathology report is not provided by customer , LILAC proceed with H & E staining followed by histopathology remarks along with marking of tumor area by our consultant pathologist.
- Assays are performed in accordance with standard procedure on receipt. The reported results are dependent on individual assay methods, equipment used, method specificity, sensitivity and quality of specimen(s) received.
- Lilac Insights Pvt. Ltd. has policy to return the FFPE blocks within one month after final reporting with proper documentation of the dispatch of the block to customer from accession dept, Lilac. After dispatch, if there is no intimation from customer within two weeks, Lilac will not be responsible for the Dispatched FFPE block.
- Soft copies of oncocytogenetics reports are sent to customer by office mail ID. Also, Hardcopies are sent to customer only on the address provided by client.